

LEARNING OBJECTIVES

- 1) Recognize and understand the consequences of the anti-MDA-5 subtype of dermatomyositis (DM)
- 2) Recognize ILD as a common complication of DM which is more severe in the MDA-5 subtype
- 3) Understand treatment options for ILD associated with MDA-5 DM

CASE PRESENTATION

- A 38-year-old male of Japanese descent presented with two months of recurrent fevers, polyarthritis, rash, dyspnea, 30lb weight loss, dysphagia, odynophagia, and weakness.
- Medical history: none
- Social history: weekly marijuana use, no tobacco or alcohol use
- Family history: mother with rheumatoid arthritis
- Medications: none

PHYSICAL EXAM

Vitals: Temp 37 °C (98.6 °F), BP 112/82, HR 105, RR 17, SpO₂ 96% on 2L O₂, 70.8 kg (from 84.8 kg two mo. prior)

Heliotrope rash → Generally tired appearing, hoarse voice

Chilblains-like lesions and Gottron's papules

Diffuse joint tenderness

Proximal muscle weakness

Poor inspiratory effort with normal breath sounds bilaterally

LABS

Basic Workup:

- CBC and smear with normocytic anemia and no evidence of neoplasm
- BMP within normal limits
- LFTs with **acute hepatocellular liver injury**
- **CK 381, Ferritin 3,854**
- CRP 3.2, ESR 36

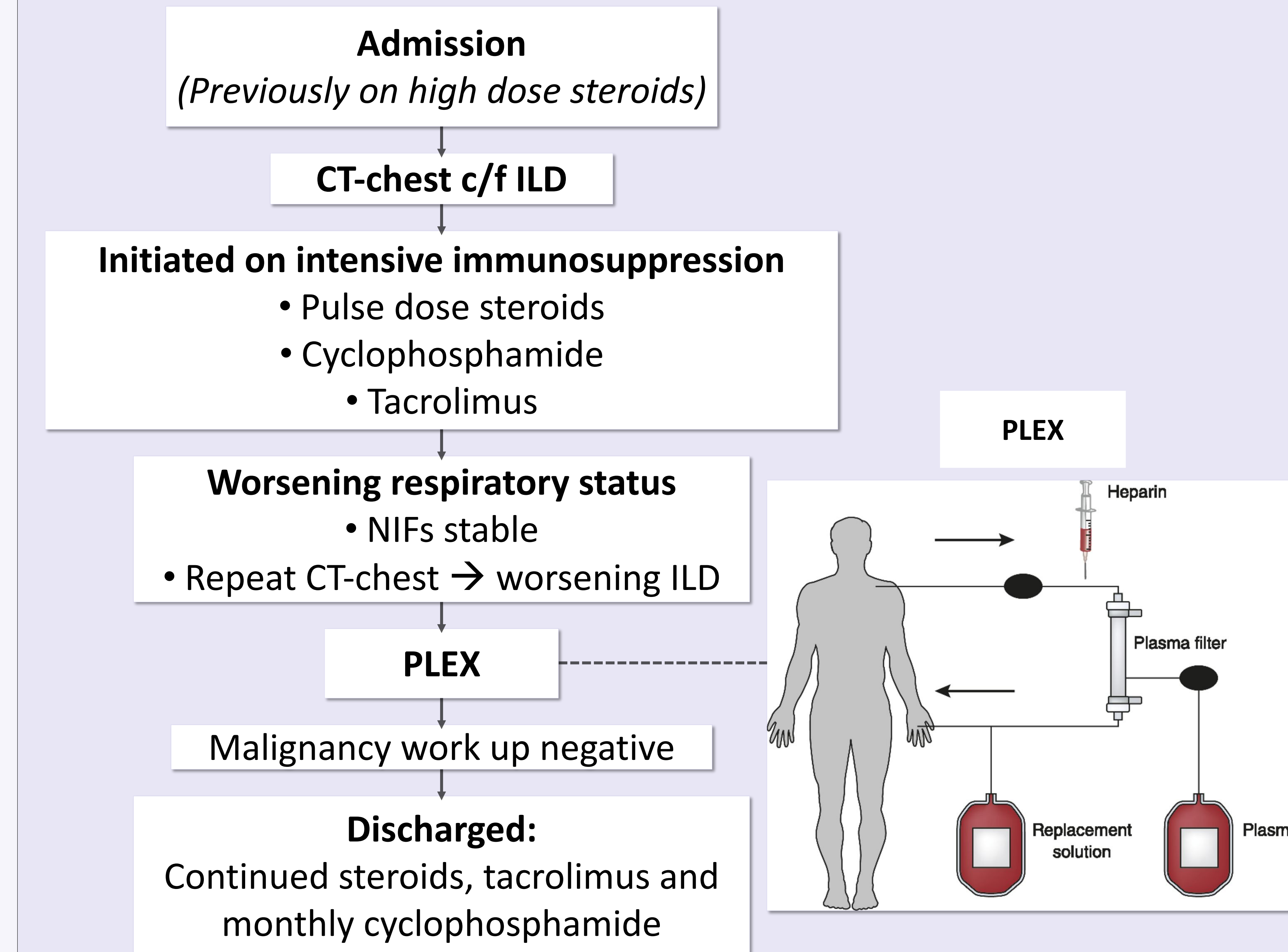
Additional infectious workup:

- Negative viral serologies (HIV, HBV, HCV, EBV, CMV, Parvo-B19)
- Negative atypical infectious workup (TB, Brucella, Bartonella, RMSF, Francisella, Treponema)

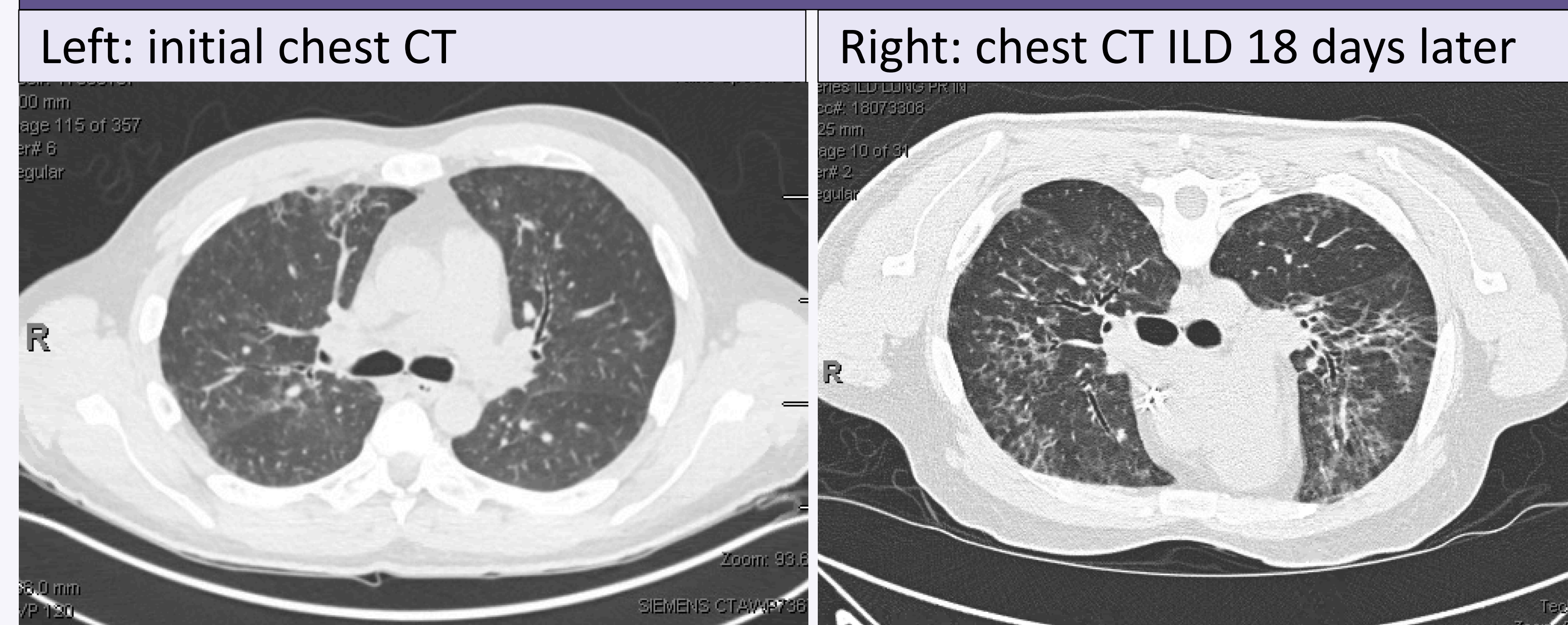
Auto-antibodies:

- **ANA 1:1280**
- **+anti-MDA-5 (CADM-140)**
- **+anti-SSA (Ro)**
- negative RF and ANCA

DISEASE COURSE



IMAGING



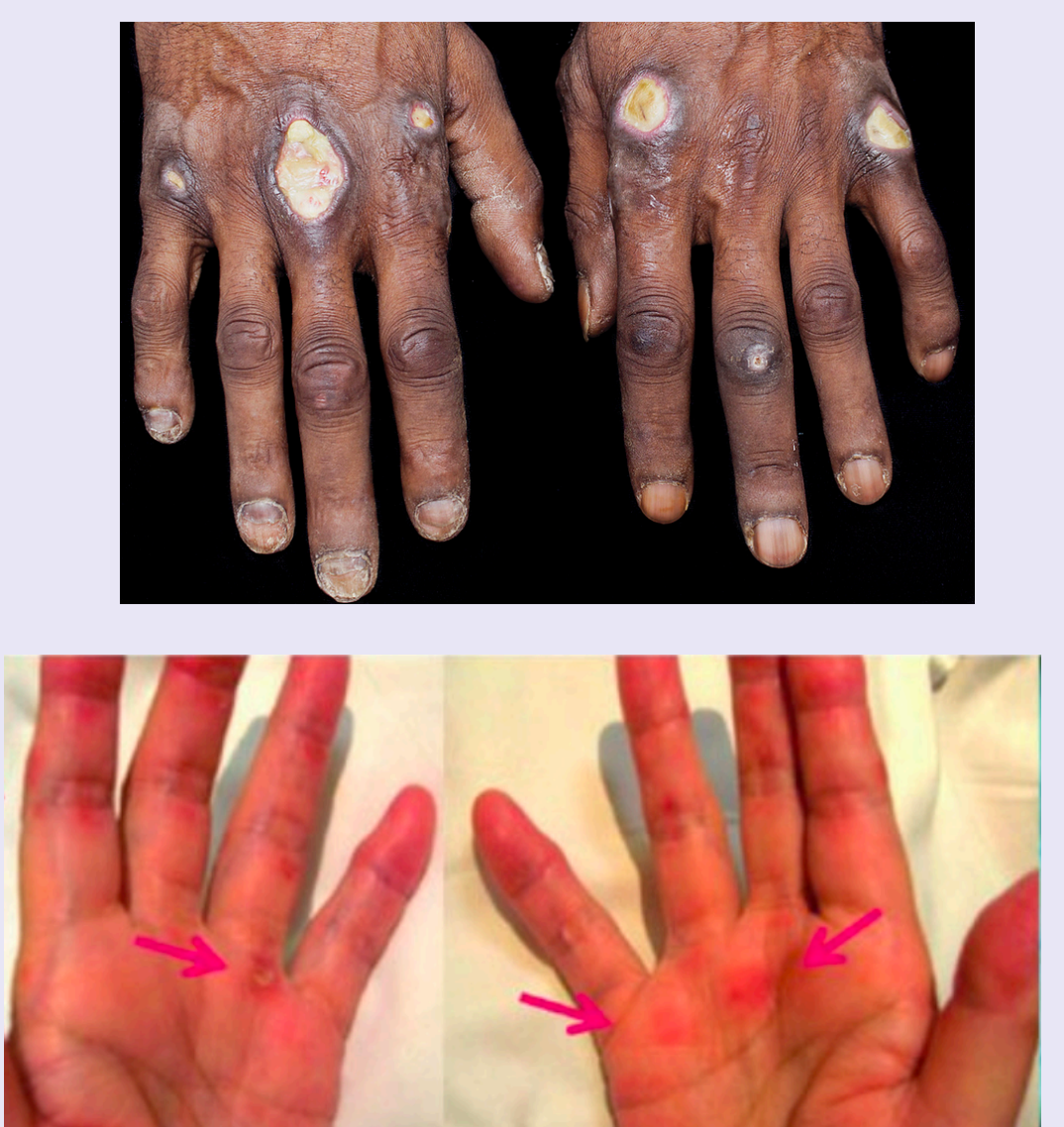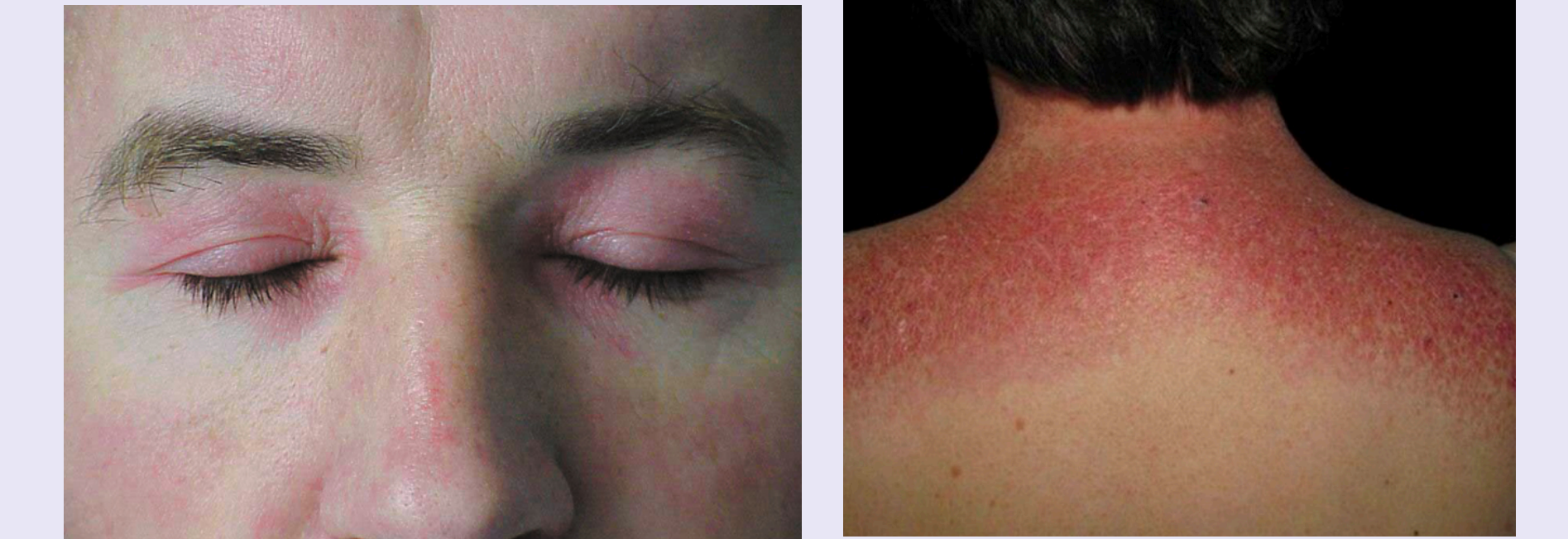The repeat CT shows an increase in bilateral upper lobe ground glass opacities with septal thickening, architectural distortion/volume loss, and bronchiectasis.

References:

1. Cheeti A, Brent LH, Pangnikk S. Autoimmune Myopathies. [Updated 2020 Aug 10]. In: StatPearls [Internet]. Treasure Island (FL): StatPearls Publishing; 2020 Jan-. Available from: <https://www.ncbi.nlm.nih.gov/books/NBK532850/>
2. Bendewald MJ, Wetter DA, Li X, Davis MD. Incidence of Dermatomyositis and Clinically Amyopathic Dermatomyositis: A Population-Based Study in Olmsted County, Minnesota. *Arch Dermatol.* 2010;146(11):26-30. doi:10.1001/archdermatol.2009.328
3. Bendewald MJ, Wetter DA, Li X, Davis MD. Incidence of dermatomyositis and clinically amyopathic dermatomyositis: a population-based study in Olmsted County, Minnesota. *Arch Dermatol.* 2010 Jan;146(1):26-30. doi:10.1001/archdermatol.2009.328. PMID: 20083689; PMCID: PMC2886726.
4. Satoh M, Tanaka S, Ceribelli A, Calise SJ, Chan EK. A Comprehensive Overview on Myositis-Specific Antibodies: New and Old Biomarkers in Idiopathic Inflammatory Myopathy. *Clin Rev Allergy Immunol.* 2017 Feb;52(1):1-19. doi:10.1007/s12016-015-8510-y. PMID: 26424665; PMCID: PMC5828023.
5. Chaisson NF, Paik J, Orbal AM, Casciola-Rosen L, Fiorentino D, Danoff S, Rosen A. A novel dermato-pulmonary syndrome associated with MDA-5 antibodies: report of 2 cases and review of the literature. *Medicine (Baltimore).* 2012 Jul;91(4):220-8. doi:10.1097/MD.0b013e31826060b. PMID: 2232950; PMCID: PMC3726263.
6. Ye S, Chen XX, Lu XY, et al. Adult clinically amyopathic dermatomyositis with rapid progressive interstitial lung disease: a retrospective cohort study. *Clinical Rheumatology.* 2007 Oct;26(10):1647-1654. DOI: 10.1007/s10067-007-0562-9.
7. Connors GR, Christopher-Stine L, Oddis CV, Danoff SK. Interstitial lung disease associated with the idiopathic inflammatory myopathies: what progress has been made in the past 35 years? *Chest.* 2010 Dec;138(6):1464-74. doi:10.1378/chest.10-0180. PMID: 21138882.
8. Hamaguchi Y, Kuwana M, Hoshino K, et al. Clinical Correlations With Dermatomyositis-Specific Autoantibodies in Adult Japanese Patients With Dermatomyositis: A Multicenter Cross-sectional Study. *Arch Dermatol.* 2011;147(4):391-398. doi:10.1001/archdermatol.2011.52
9. Gono T, Kawaguchi Y, Satoh T, Kuwana M, Katsumata Y, Takagi K, Masuda I, Tochimoto A, Baba S, Okamoto Y, Ota Y, Yamanaka H. Clinical manifestation and prognostic factor in anti-melanoma differentiation-associated gene 5 antibody-associated interstitial lung disease as a complication of dermatomyositis. *Rheumatology (Oxford).* 2010 Sep;49(9):1713-9. doi:10.1093/rheumatology/keq149. Epub 2010 May 23. PMID: 20498012.
10. Gono T, Kawaguchi Y, Ozeki E, Ota Y, Satoh T, Kuwana M, Hara M, Yamanaka H. Serum ferritin correlates with activity of anti-MDA5 antibody-associated acute interstitial lung disease as a complication of dermatomyositis. *Mod Rheumatol.* 2011 Apr;21(2):223-7. doi:10.1007/s10165-010-0371-x. Epub 2010 Nov 5. PMID: 21052763.
11. Gono T, Kawaguchi Y, Hara M, Masuda I, Katsumata Y, Shinozaki M, Ota Y, Ozeki E, Yamanaka H. Increased ferritin predicts development and severity of acute interstitial lung disease as a complication of dermatomyositis. *Rheumatology (Oxford).* 2010 Jul;49(7):1354-60. doi:10.1093/rheumatology/keq073. Epub 2010 Apr 12. PMID: 20385617.
12. Cherin P, Auperin I, Buzsai A, et al. Plasma exchange in polymyositis and dermatomyositis: a multicenter study of 57 cases. *Clin Exp Rheumatol.* 1995; 13: 270-271.
13. Herson S, Lok C, Roujeau JC, et al. Plasma exchange in dermatomyositis and polymyositis. Retrospective study of 38 cases of plasma exchange. *Ann Med Interne (Paris)* 1989; 140: 453-455.67.

DISCUSSION

- **Dermatomyositis (DM) is a rare idiopathic inflammatory myopathy with an annual incidence of 1 in 100,000 (1).**
- **DM is characterized by distinctive cutaneous and MSK findings**
 - Heliotrope rash
 - Gottron's papules
 - V-sign and shawl sign
 - Symmetrical, proximal muscle weakness
- **DM is associated with ILD**
 - 35-40% of patients with DM will be affected by ILD (7).
 - 93% with a positive MDA-5 antibody (8).
- **MDA-5 antibody DM is a subtype with specific features**
 - Higher incidence in Asian populations (3).
 - Lower risk of malignancy (4).
 - Characteristic cutaneous findings (5).
 - More rapidly progressive form of ILD
 - Carries up to a 40% 6-month mortality rate (6).



- Hyperferritinemia with levels >1,600 ng/ml has been associated with worse prognosis (9-11).
- Plasma exchange and IVIG have been used for the treatment of ILD in DM, however, plasma exchange may be best for severe acute forms of the disease (12, 13).
- Determining the cause of hypoxemia in DM requires distinguishing myositis-associated respiratory muscle weakness from progression of ILD.

CONCLUSIONS

- Pathognomic features of dermatomyositis include the heliotrope rash and Gottron's papules.
- The anti-MDA-5 subtype is important to recognize as it is associated with rapidly progressive ILD and poor prognosis; it should be suspected when there is early lung involvement and characteristic skin findings and should be treated aggressively with plasma exchange.
- Ferritin levels >1,600 ng/ml portend worse prognosis.