

Using Immunomodulatory Drugs in Patients with Autoimmune Conditions: A Therapeutic Challenge

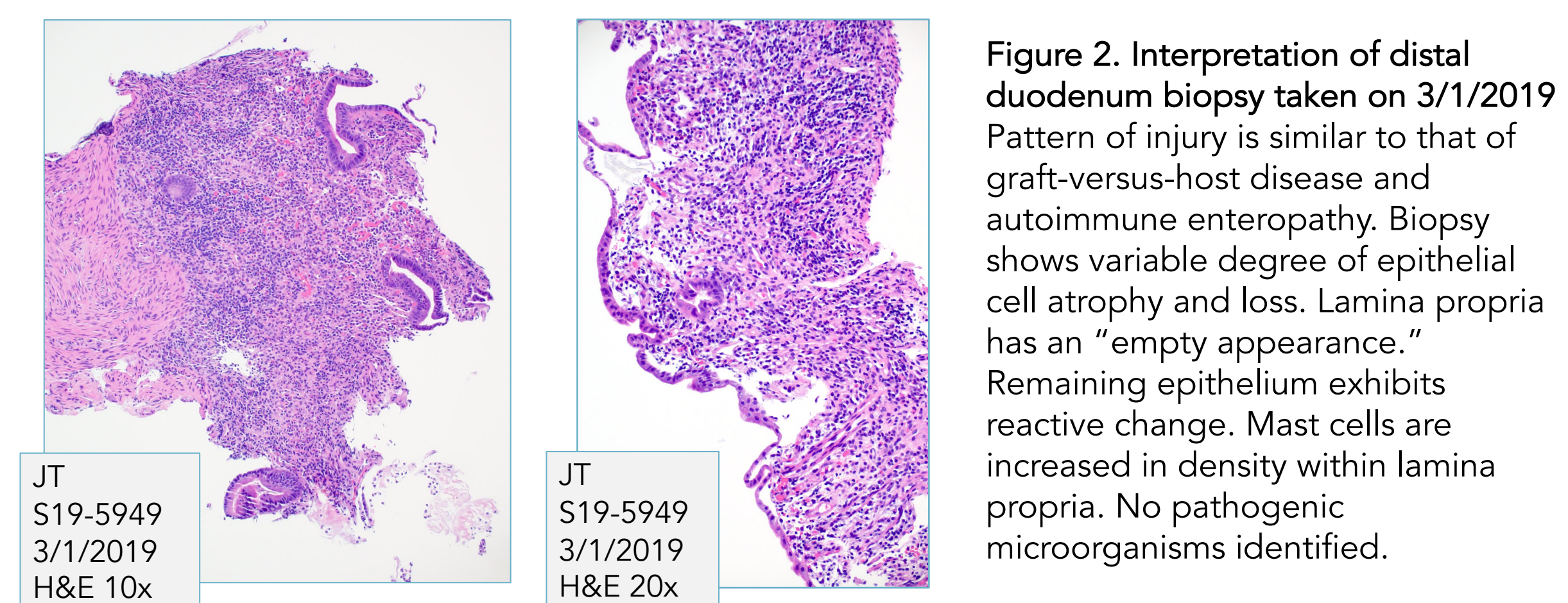
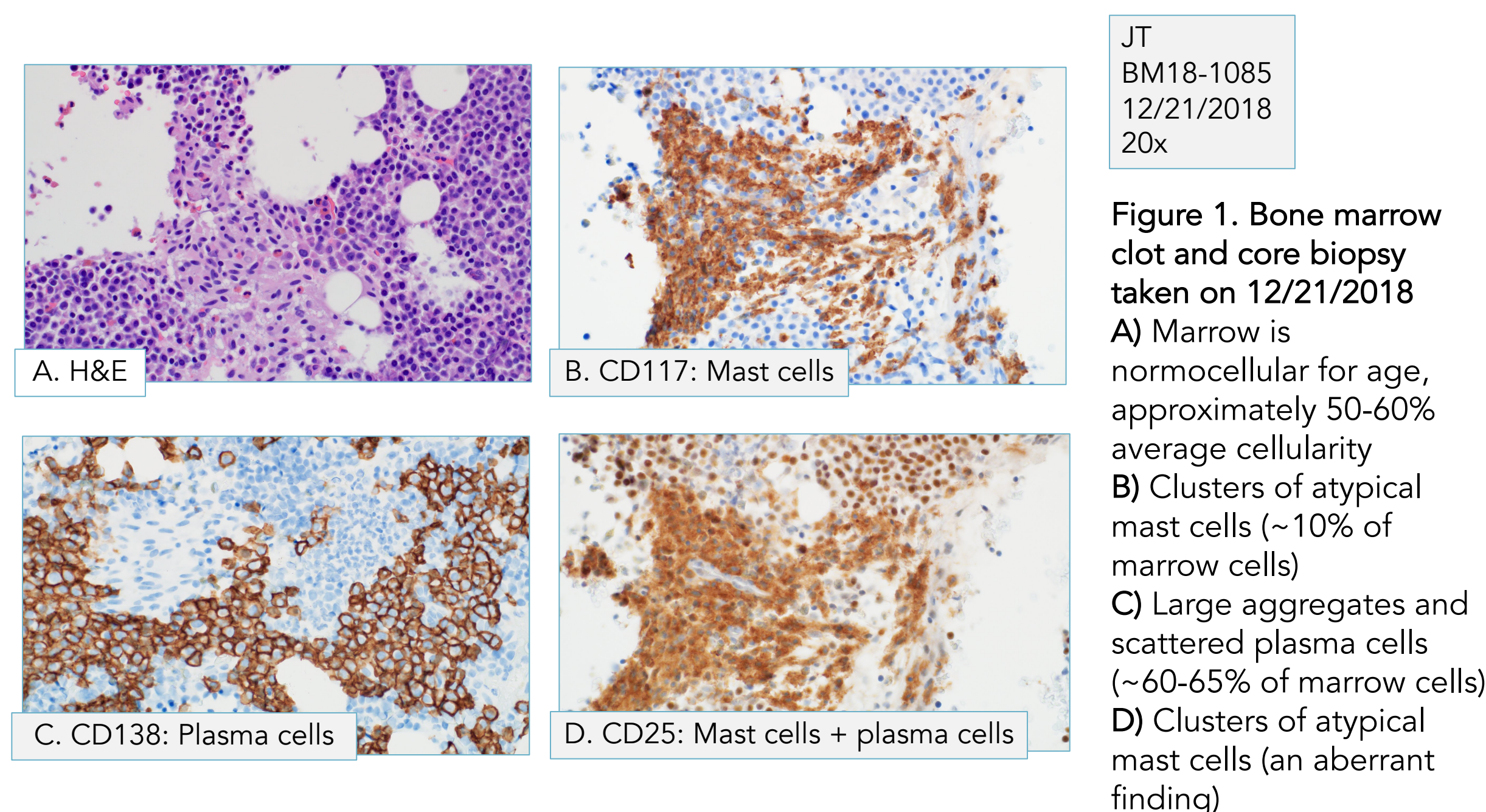
Andy V. Truong, MSc¹; Tomer M. Mark, MD, MSc²

¹University of Colorado School of Medicine ²University of Colorado School of Medicine – Division of Hematology

INTRODUCTION

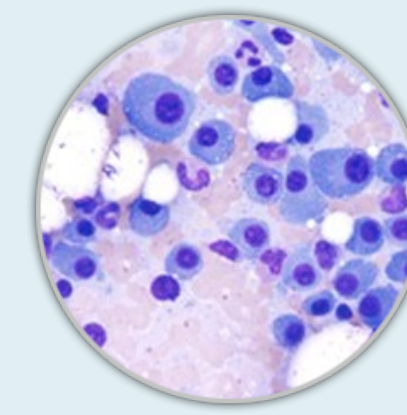
- Systemic mastocytosis (SM) is a rare hematological neoplasm defined by multifocal dense infiltrates of mast cells in bone marrow and extracutaneous organs¹. A wide range of symptoms may present, most commonly cutaneous manifestations.
- Multiple myeloma (MM) is a malignancy of plasma cells that accounts for 10% of all hematologic cancers².
- Systemic mastocytosis with associated hematologic neoplasm (SM-AHN) is a clonal stem cell disease that occurs concurrently with SM¹.
- The treatment of SM-AHN is primarily dictated by the non-mast cell neoplasm³.
- Recent advancements in the treatment for MM have led to an increase in the usage of immunomodulatory agents (IMiDs), as they have been shown to be highly effective⁴. The IMiDs activate immune effector cells as part of their anti-neoplastic mechanism of action.
- This case of SM-AHN with MM illustrates the complex dynamics between IMiD use, mast cell activation, and MM treatment.

FIGURES



CASE SUMMARY

August 2, 2018



Dx: MULTIPLE MYELOMA

- PMH: Urticaria pigmentosa (dx 1992)
- Labwork:
 - SPEP 2.7g/dL M-spike, isotype IgA-kappa
 - IgA 3201 mg/dL
- Bone marrow biopsy (Figure 1):
 - Systemic mastocytosis with associated hematologic neoplasm (SM-AHN) – 50% plasma cells

January 12, 2019



FIRST-LINE TREATMENT (BiRd Regimen)

- Lenalidomide + Dexamethasone
- Clarithromycin augmentation

January 16, 2019



TELEPHONE ENCOUNTER / URGENT EVAL

- Patient reported worsening itching on head/face
 - Treated symptomatically with hydroxyzine
- Cough / Fever (101.4F) / Rhinorrhea
 - Treated empirically with levofloxacin for suspected URI, symptoms resolved

February 24, 2019



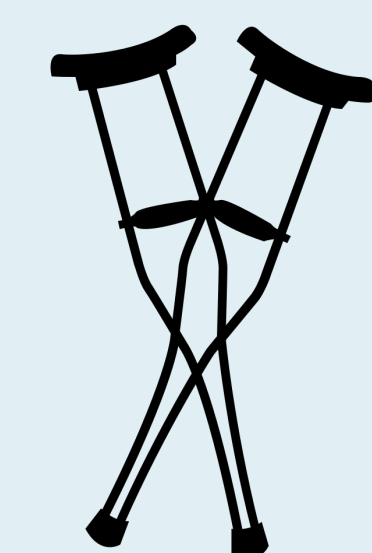
ED ADMISSION

- Severe diarrhea (>12 episodes per day)
- Diffuse crampy abdominal pain
- No alleviation with Lomotil and imodium
- Rd regimen (HOLD: 2/22/19)
- Labwork negative for most infectious causes

DUODENUM/TERMINAL ILEUM/COLON BIOPSIES

- Pattern of injury reminiscent of graft-vs-host disease, autoimmune enteropathy, and some medication related injury (Figure 2)
- Mast cell density is increased
- Negative for CMV, HSV, histo/fungal, congo red

March 12, 2019



HOSPITAL DISCHARGE

- Dx: Immune mediated enteropathy likely related to lenalidomide (Revlimid)
- Discharged with Prednisone 100mg PO
- Tapered steroids, continued holding BiRd
- MM had good response from prior treatment: IgA 3951 mg/dL (1/8/19) to 2280 (2/6/19)

May 25, 2019



SECOND-LINE TREATMENT

- Ixazomib (Ninlaro) + Dexamethasone + Zofran
- Daratumumab augmentation (8/30/19)
- IgA 1299 (8/30/19) to 402 (1/17/20)

DISCUSSION

- The anti-melanoma mechanism of lenalidomide is thought to be due to enhanced activation of T-cells via the immune-modulatory effect and NK cell-mediated cytotoxicity⁵.
- The same mechanism of lenalidomide, stimulating proinflammatory CD4 cells and increased CD8/IFN- γ cells, is thought to be responsible for graft-versus-host disease in post-allograft stem cell transplant patients⁶.
- Though the mechanism has not yet been completely elucidated, T cells and mast cells communicate with each other, as T cells have been shown to signal release of inflammatory cytokines from mast cells⁷ and activate them in an IgE-independent manner⁸.
- Stimulating T cells in a patient with mast cell proliferation has the potential to exacerbate immune responses.
- Patients with autoimmune conditions being treated with immunomodulatory drugs should be meticulously monitored for immune complications such as autoimmune enteropathy as seen in this case.
- The treatment outcomes of multiple myeloma regimens continue to have high degrees of variance, accentuating the importance of personalized medicine.

REFERENCES

- Radia D, et. al. Review of the clinical and pathological panoply of systemic mastocytosis. BJH. 2019.
- Kyle R and Rajkumar SV. Multiple myeloma. Blood. 2008;111(6).
- Pardanani A. Systemic mastocytosis in adults: 2017 update on diagnosis, risk stratification and management. AJH. 2016;91(11).
- Rossi A, et. al. BiRd (clarithromycin, lenalidomide, dexamethasone): an update on long-term lenalidomide therapy in previously untreated patients with multiple myeloma. Blood. 2013;121(11).
- Kneppers E, et. al. Lenalidomide maintenance after nonmyeloablative allogeneic stem cell transplantation in multiple myeloma is not feasible: results of the HOVON 76 Trial. 2011;118(9).
- Wolschke C. Postallograft lenalidomide induces strong NK cell-mediated antimyeloma activity and risk for T cell-mediated GvHD: Results from a phase I/II dose-finding study. Experimental Hematology. 2013;41.
- Shefler I, et. al. T Cell-induced mast cell activation: A role for microparticles released from activated T cells. Journal of Immunology. 2010;185.
- Velez TE, et. al. Mast cell interactions and crosstalk in regulating allergic inflammation. Current Allergy and Asthma Reports. 2018;18(30).